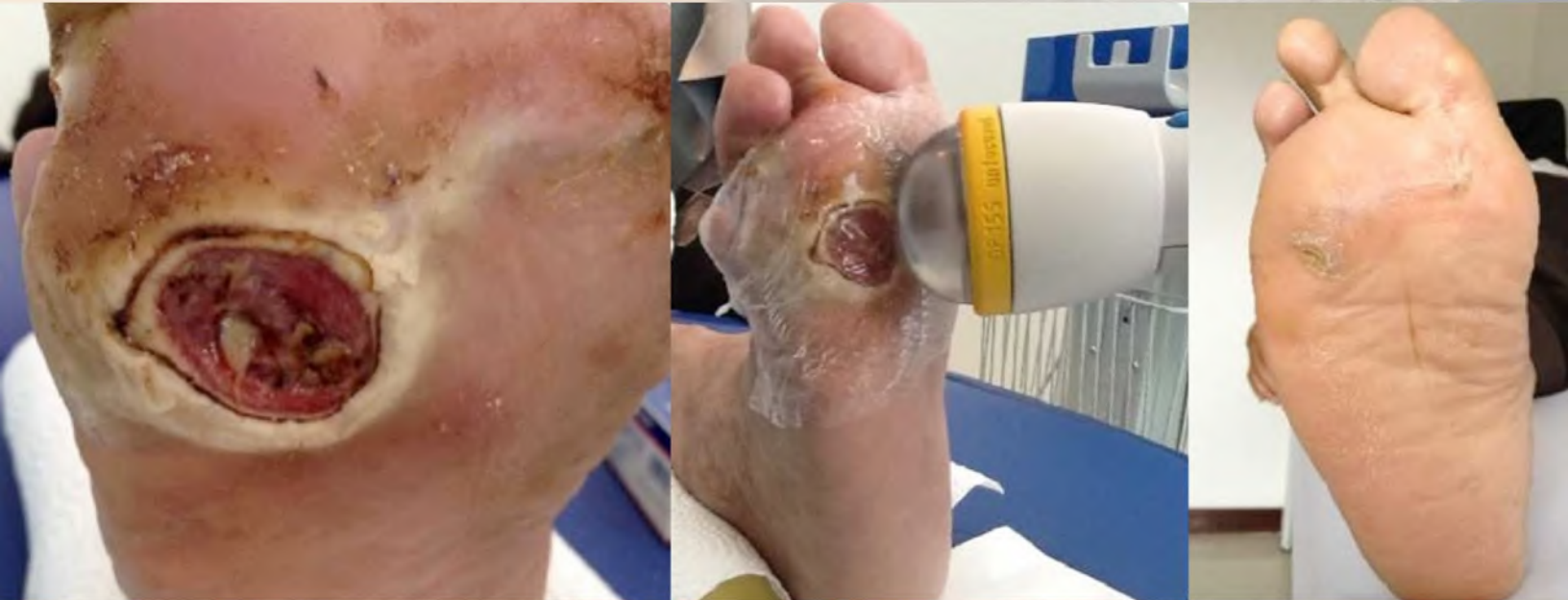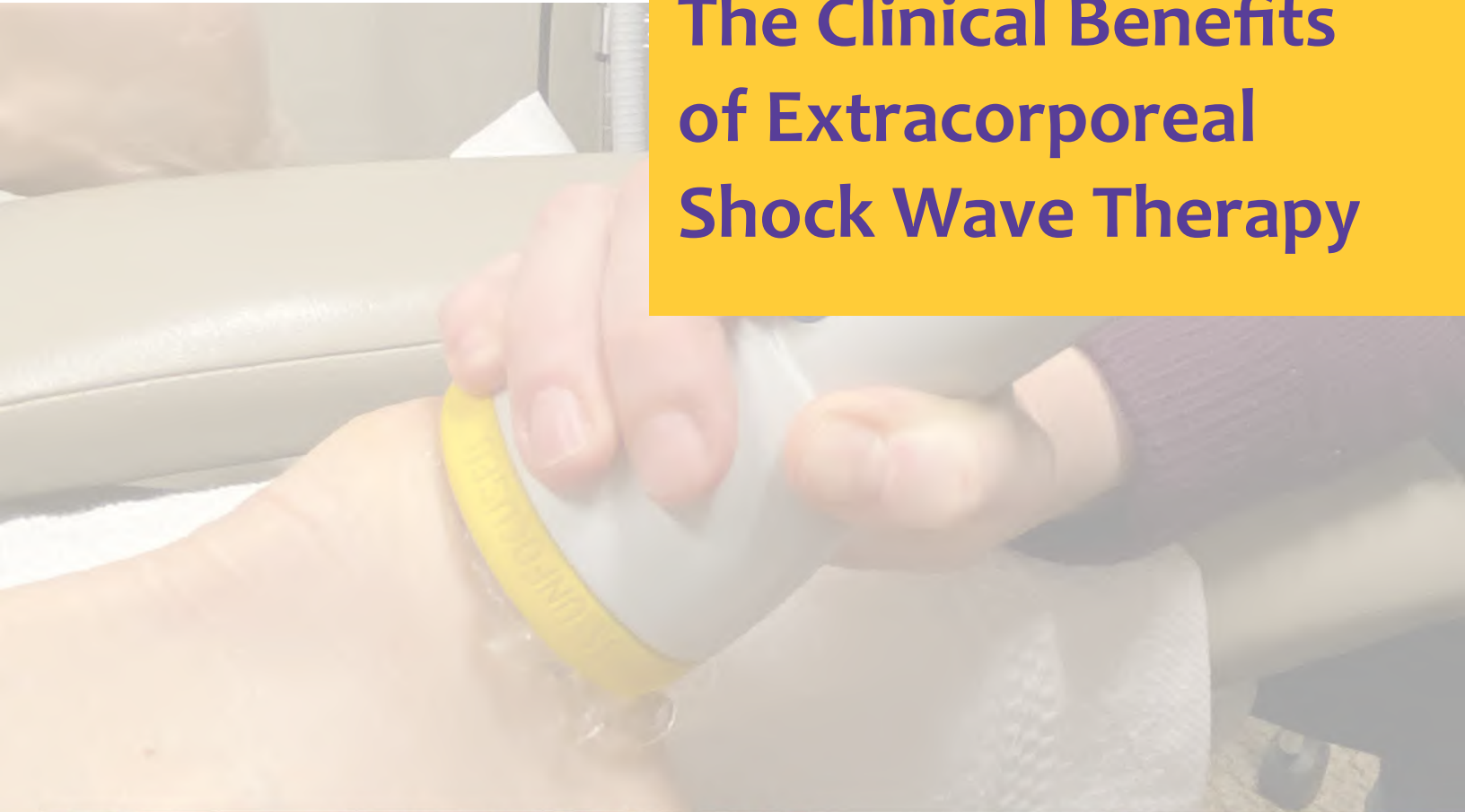

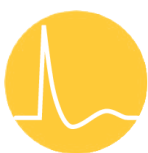
CARING FOR WOUNDS

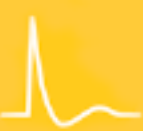# The Clinical Benefits of Extracorporeal Shock Wave Therapy



**62-year-old DFU patient after 4 SoftWave sessions**



**SoftWave**  
Tissue Regeneration Technologies



# The High Cost of Wound Care

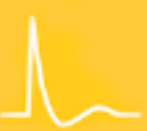---

Wound management, including acute and trauma wounds, is a clinical challenge across all care settings and one with high associated costs. In the United States, approximately 5% of hospital budgets is devoted to wound care. The total national cost is between \$28.1 billion and \$96.8 billion dollars a year.<sup>1</sup> Complex and chronic wounds often take longer to heal, and this delay significantly increases the cost of treatment.

Diabetic foot ulcers (DFUs) are among the most common types of wounds associated with recurrence and chronicity. Over one-third (35%) of patients with diabetes who are seen in clinics are patients with a DFU. Treatment of diabetic ulcers in the United States contributes an additional \$9-\$13 billion to the direct annual costs associated with diabetes.<sup>2</sup> These wounds are painful and difficult to treat, and they represent a tremendous burden on the national health care system.

Acute, traumatic, and incisional wounds also present significant clinical challenges, particularly complex soft tissue wounds, such as burns. Treating burns is also very expensive. In 2014, the average cost for patients who were hospitalized for burn care and survived (96.7%) was \$86,146. For the 3.3% of patients who died of their injuries despite treatment, the average cost was \$285,225.<sup>3</sup> In addition, even clean cuts made during surgery can be prone to complications. Between 30% and 60% of surgical wounds become infected.<sup>4</sup> These soft tissue wounds severely impact patients' quality of life, especially during a prolonged healing phase. These wounds can also present many clinical challenges to treatment. Decreasing healing time can help many patients avoid unnecessary complications.

Extracorporeal shock wave therapy (ESWT) is a non-invasive therapy that has proven therapeutic effects for DFUs,<sup>5</sup> second-degree burns,<sup>5</sup> and other wounds, including post-operative incisions and traumatic lesions. To understand why ESWT works with these types of wounds, it is important to understand the above wound etiologies and characteristics.



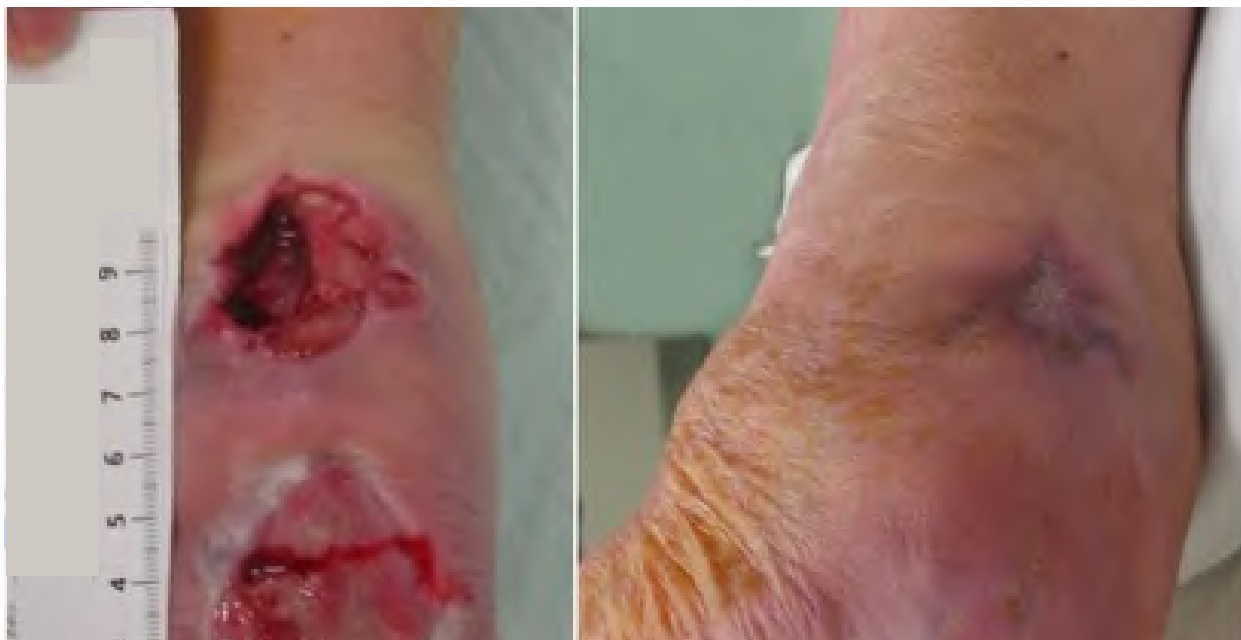## Etiologies

### Diabetic foot ulcers

DFUs are among the most common complications of diabetes mellitus. These wounds are caused by peripheral neuropathy, small vessel occlusion, and secondary infection or trauma.<sup>6</sup> Because DFUs have a complex etiology and have various interactions between local and systemic factors, treatment established in current guidelines is not always successful.<sup>7</sup> Patients with DFUs often experience pain and are likely to have a recurrence when the DFU does heal. Approximately 40% of patients will experience recurrence within three years and 65% within five years.<sup>8</sup> Severe ulcers may lead to amputation of part of the lower extremity (LE).

DFUs have an extreme effect on patients with these wounds. These patients often feel socially isolated and may have limited mobility, sometimes to the extent that simple, daily tasks are impossible to perform. They also commonly have pain and discomfort. The widespread effects of DFUs often worsen patients' quality of life and can even lead to depression.

Although numerous treatment strategies are commonly used to aid healing of DFUs, such as negative pressure wound therapy, ultrasound, recombinant human platelet-derived growth factor-BB, and acellular matrix products, these treatment strategies often have low efficiency, potential side effects, and high costs.<sup>8</sup> Even with individualized care, such as frequent repositioning, debridement, and monitored glucose control, some DFUs fail to progress through the stages of healing.<sup>7</sup> ESWT is a non-invasive treatment method that can have a positive impact on healing DFUs.



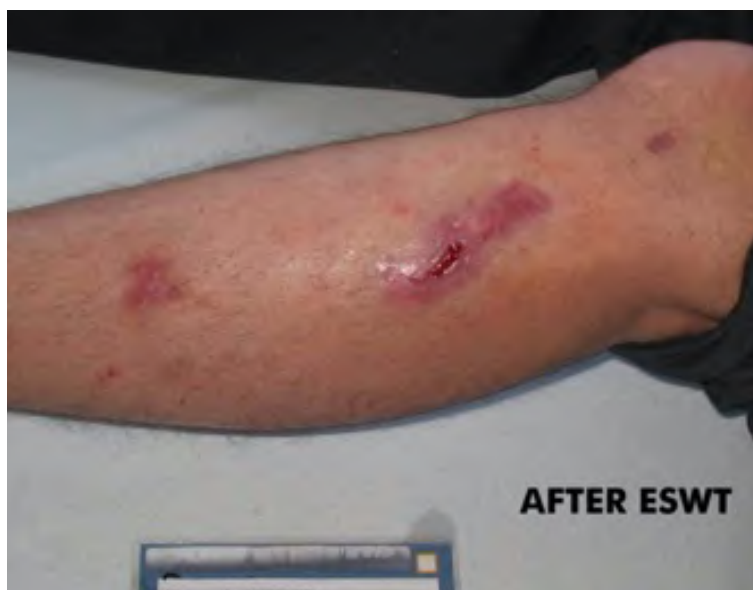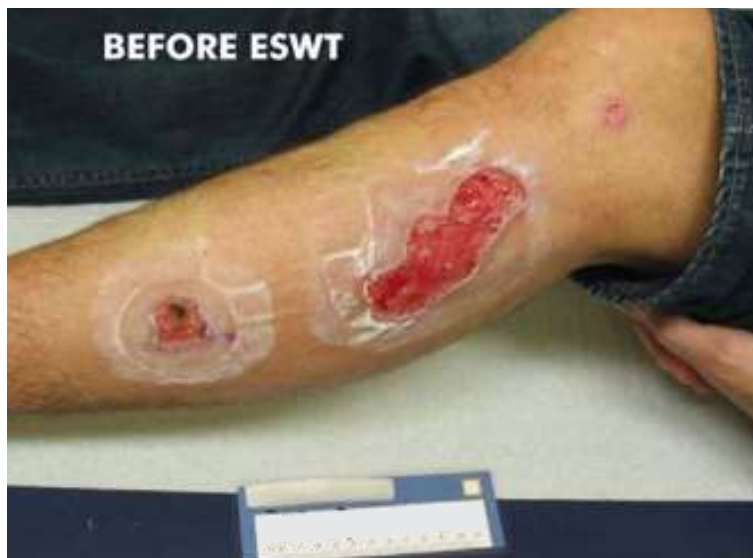*Diabetic foot ulcer after surgical intervention  
71 years old, female, diabetic; 5 SWT treatments in total, 2,500 impulses*



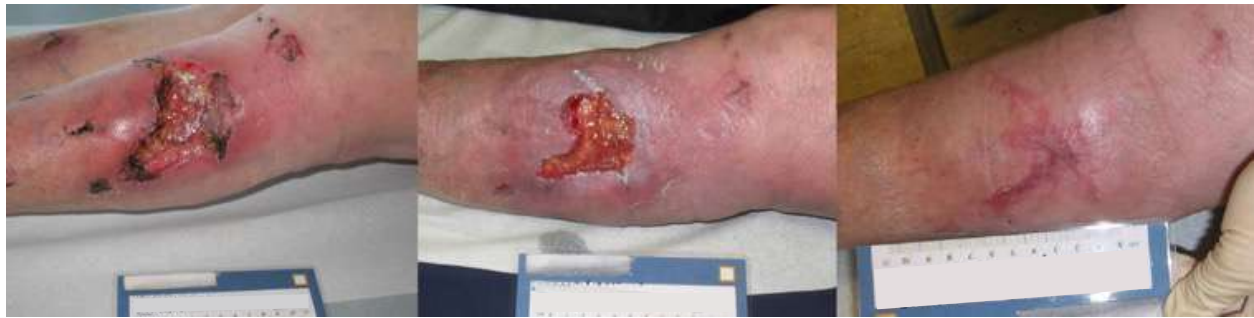## Second-degree burns

Burns are among the most complex forms of injury. Unlike first-degree burn injuries, second-degree burns damage the outer layer of skin and the layer underneath. There are two types of second-degree burns, superficial partial-thickness burns and deep partial-thickness burns. Superficial partial-thickness burns affect the epidermis and papillary dermis. Deep partial-thickness burns also extend to the reticular dermis. The burn will appear red and white, with slow capillary refill. Thick-walled blisters are commonly present.<sup>9</sup>

Burns can have various etiologies depending on the source of the injury, and they are among the most complex injuries to treat. Patients who have been burned often face physiological and psychological trauma, and the pain resulting from burns is often described as the most severe pain felt by patients.<sup>10</sup> Controlling the patient's pain level and managing the threat of infection are two of the greatest challenges for clinicians treating these types of wounds. ESWT can aid in the treatment of burn wounds by increasing perfusion and assisting epithelialization.<sup>11</sup>



*Burn injury  
Before and after 7 weeks / 4 SWT sessions applied in total*



*Infected dog bite*

*Before, after 3 weeks, and after 11 weeks / 4 sessions of SWT applied*

## Traumatic and surgical wounds

Traumatic wounds, or wounds caused by injury, can range from abrasions to minor skin incisions to injuries with extensive tissue damage that impact the bone or internal organs. Surgical wounds are those created intentionally during surgical procedures. Both of these types of wounds can have complications, including infection, which can cause them to be considered non-healing or complex wounds.<sup>12</sup>

Treating these types of wounds is a significant challenge because of underlying complexities of the wounds, an aging population, and increases in diabetes and obesity. All of these conditions contribute to aberrant wound healing.<sup>12</sup>

## Extracorporeal Shock Wave Therapy

ESWT has been widely used to treat musculoskeletal disorders, myocardial infarction, wound healing, and erectile dysfunction. It is a non-invasive treatment method that is cost-effective and has negligible side effects for patients.<sup>5</sup> This type of therapy generates shock waves outside the body and transmits the acoustic energy inside the body to induce therapeutic effects.

Evidence indicates that the release of energy can generate a cellular response through mechanotransduction,<sup>18</sup> thus enabling a host of biological effects.<sup>17</sup> As a type of acoustic wave, a shock wave carries energy that can be directed and targeted to impact selected tissue non-invasively.<sup>17</sup>



### Types of Shock Wave

The way in which the shock waves are produced and delivered varies by the condition treated. These variations are broken into the following categories:

- **Focused:** This category includes electrohydraulic, electromagnetic, and piezoelectric devices.<sup>13</sup>
  - **Low-intensity electromagnetic and piezoelectric devices:** These treatments rely on directing the energy produced to a focal point within the tissue where its concentration causes a shock wave to form.<sup>14</sup>
  - **Low-intensity electrohydraulic devices:** A shock wave is produced at the source inside the applicator head, and a second shock is then produced within the tissue at the fixed focal length.<sup>12</sup>

- **Unfocused:** Unfocused shock wave therapy is limited to the electrohydraulic method for reasons involving both physics and patents.<sup>11</sup> Radial acoustic pressure pulse devices are also unfocused, but they are not considered ESWT devices because they produce a different

waveform.<sup>15</sup> Energy is dispersed in a wide pattern with no focal point or secondary shock wave.<sup>16</sup> These shock waves initiate the same biological response as focused therapy, but they have a much larger shock wave zone, which can increase the efficiency of treatment and reduce the risk by eliminating high energy concentrations at focal points.<sup>14</sup> Unfocused shock wave therapy is generally tolerated by patients better and does not require local or general anesthesia.

---

The variability in the types of shock waves is one reason the exact mechanism of shock wave therapy's healing abilities is not fully understood.

---

ESWT can be further separated into low-intensity (energy flux density  $<0.1$  mJ/mm<sup>2</sup>), medium-intensity (energy flux density,  $0.1$ – $0.2$  mJ/mm<sup>2</sup>), and high-intensity (energy flux density  $\geq 0.2$  mJ/mm<sup>2</sup>) treatments. One meta-analysis previously suggested that medium-intensity ESWT (MIESWT) was more effective than a control therapy.<sup>19</sup>

The variability in the types of shock waves is one reason the exact mechanism of shock wave therapy's healing abilities is not fully understood. The shock waves in unfocused ESWT are referred to as “soft” waves, which have the advantage of distributing maximum energy in a wide and deep pattern, thereby allowing treatment of a larger area.<sup>16</sup>



## Conditions treated with ESWT

Recent studies have noted that ESWT can be used to treat a wide range of conditions, including complex and chronic non-healing soft tissue wounds<sup>22</sup> with different etiologies, such as DFUs, peripheral arterial diseases, venous leg ulcers, and pressure ulcers.<sup>5</sup> Several research studies looking at the efficacy of unfocused shock wave therapy and technologies have found similar positive results. This therapy was found to be well tolerated by patients with acute and chronic wounds,<sup>24</sup> demonstrated positive results in short-term and long-term outcomes in diabetic patients with DFUs,<sup>25</sup> and improved wound healing after vein harvesting for coronary artery bypass graft surgery.<sup>26</sup> These are just a few types of injuries that can benefit from ESWT.

ESWT is an evidence-based, non-invasive, convenient treatment for chronic wounds, including DFUs. It is an adjunctive therapy that can be combined with standard wound care therapies, such as debridement, infection control, dressing application, and others.<sup>20</sup> One study found that using ESWT to treat chronic wounds resulted in nearly three-fourths (74.03%) of wounds closing and not reappearing in the same location.<sup>21</sup>

ESWT can also significantly reduce pain surrounding a wound by modulating substance P and calcitonin gene-related peptides.<sup>4</sup> Moreover, a meta-analysis that looked at five randomized studies implementing EWST across multiple types of wounds, including burns and DFUs, found a 20% absolute efficacy advantage for ESWT relative to control treatments and achievement of 50% of the performance goals outlined for ESWT effectiveness.<sup>23</sup>

When used to treat burn injuries, ESWT has been found to relieve pain, decrease pruritus, and improve health-related quality of life for these patients.<sup>19</sup> It has also shown promise for use in regenerating and remodeling tissue, which can aid in both wound healing and treatment of burn scars.<sup>10</sup> The ability of ESWT to regenerate and remodel tissue can also benefit incisional and traumatic wounds. The data support that ESWT effectively reduces healing time and helps non-healing DFUs and complex second-degree burns heal more quickly and effectively.

**Table 1. Wound area change from baseline at 12 weeks. ITT/MITT and EE population, study 1**

Treatment group	Total number of paired subjects at 12 weeks	Baseline average wound area (cm <sup>2</sup> )	Average wound area at 12 weeks (cm <sup>2</sup> )	Average wound area reduction (cm <sup>2</sup> )	p-value
ESWT (ITT/MITT with LOCF)	107	3.5	1.8	-1.7 (48.6%)	0.015
Sham-control (ITT/MITT with LOCF)	99	2.8	2.6	-0.3 (10.7%)	
ESWT (ITT/MITT without LOCF)	85	3.5	1.6	-1.9 (54.3%)	0.004
Sham-control (ITT/MITT without LOCF)	71	2.9	2.7	-0.2 (6.9%)	
ESWT (EE with LOCF)	101	3.5	1.7	-1.8 (51.4%)	0.022
Sham-control (EE with LOCF)	93	2.9	2.6	-0.3 (10.3%)	
ESWT (EE without LOCF)	71	3.6	1.5	-2.1 (58.3%)	0.096
Sham-control (EE without LOCF)	62	2.8	2.2	-0.5 (17.9%)	

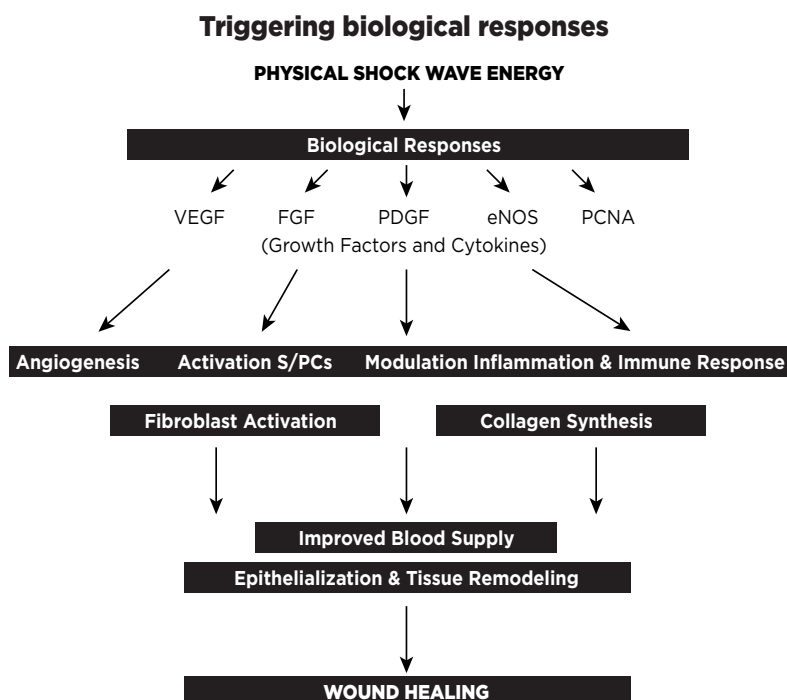
ESWT—extracorporeal shockwave therapy; EE—efficacy evaluable; LOCF—last observation carried forward; ITT—intention to treat; MITT—modified intention to treat

## Benefits of ESWT

The physiological benefits of ESWT involve increases in collagen synthesis, fibroblast proliferation, and angiogenesis. ESWT may also stimulate dermal cell metabolism and increase the growth of dermal cells required for ulcer healing. The result is a release of growth factors (including fibroblast growth factor, transforming growth factor, insulin-like growth factor-1, platelet-derived growth factor, and vascular endothelial growth factor) that trigger neovascularization of the tissue and improve the blood supply.<sup>5</sup>

From a biological perspective, ESWT has different healing impacts depending on the wound's stage of healing and characteristics:<sup>18</sup>

- **Inflammation:** Low-energy shock waves can lower the pro-inflammatory response, induce the anti-inflammatory profile in macrophages, and alter the expression of cytokines and chemokines. Shock waves also reduce leukocyte and macrophage infiltration in isograft tissue and decrease the corresponding macrophage-derived inflammatory protein response.
- **Infection:** Shock waves have a bactericidal effect and can reduce the bacterial burden of the wound. They also increase the number of microvessels and improve delivery of antibiotics to an infected wound.
- **Apoptosis and necrosis:** Shock wave treatment can decrease cellular apoptosis and reduce the necrosis of wounds.
- **Remodeling and neovascularization:** Shock wave treatment can accelerate granulation and re-epithelialization and reduce scar formation. It also increases overall blood circulation and stimulates cutaneous and muscular microcirculation.

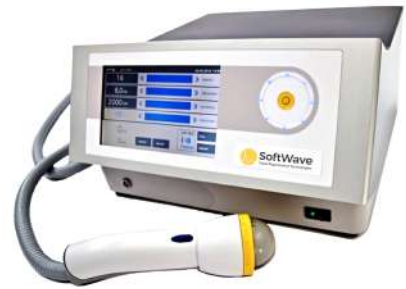





## SoftWave DermaGold 100®: Technology for Wound Management

SoftWave Tissue Regeneration Technologies DermaGold100®, manufactured by MTS Medical UG (Konstanz, Germany), is an electrohydraulic device that produces unfocused low-energy shock waves to treat a variety of acute and chronic wounds. It was first approved as a class I device by the US Food and Drug Administration (FDA) for activation of connective tissue in December 2018. It was then approved in November 2019 as a class II device to treat adults with chronic, full-thickness DFUs with a wound area greater than 16 cm<sup>2</sup>.<sup>21</sup> In 2020, the same device received FDA 510(k) clearance for the treatment of burn injuries. It is, in fact, the only ESWT therapy indicated for treating second-degree burns.



ESWT using DermaGold 100® appears to initiate a more rapid and effective healing phase. It is thought to work by:

- Increasing the blood flow to the wounded area
- Stimulating the neovascularization and growth factors
- Modulating the inflammatory process
- Stimulating osteoclasts and fibroblasts to rebuild injured tissue
- Facilitating resorption of calcification in tendons and ligaments
- Stimulating the migration of resident stem cells



Patients experience no serious side effects when using DermaGold100® for wound care.

The efficacy of DermaGold 100® is not just anecdotal. In a meta-analysis of multiple studies looking at the impact of ESWT with DermaGold 100® on wound healing, including DFUs and second-degree burns, the performance of ESWT was statistically superior to control therapies for wound healing. The success rate for ESWT was greater than 50% across seven studies. The results of the meta-analysis are consistent with a growing body of research that demonstrates the efficacy of ESWT as a wound healing therapy.



## Case Studies

---

**1**

### ***Bilateral lower extremity ulcers and edema***

The patient was an 81-year-old woman with bilateral LE ulcers and edema. She sustained a severe burn caused by a space heater in March 2018. In April of that year, she underwent multiple skin grafts, which were effective until the areas broke down in November of the same year. Wound care specialists followed up multiple times per week, first in a rehabilitation center and later during home health visits. She was prescribed multiple medications, including cephalexin for cellulitis and hydrocodone bitartrate and acetaminophen for pain. The wounds reopened and were treated with Xeroform™ and hydrocolloid dressings without improvement.<sup>21</sup>

By the time she began DermaGold 100® ESWT treatment in December of 2019, she had three persistent ulcers, and her pain score was seven out of 10. The first ulcer received treatment once weekly for a total of six sessions. The wound closed after two sessions, but it reopened after the fourth. After two additional sessions, the wound area decreased, and the wound achieved closure in early March 2020.<sup>21</sup>

**2**

### ***Bilateral lower extremity ulcers***

A 52-year-old woman with diabetes mellitus presented with non-healing bilateral LE ulcers. The first ulcer appeared on the right LE, and then the condition progressed to the left LE. Initial biopsies confirmed pyoderma gangrenosum (PG). Multiple treatments failed, including mycophenolate mofetil, methotrexate, and tacrolimus. She had been treating seven PG ulcers with daily Dakin's solution and Santyl without improvement. Six of these ulcers subsequently healed with skin grafting. The seventh ulcer had another wound next to it, which was being treated with methylprednisolone and infliximab.<sup>21</sup>

The first DermaGold 100® ESWT treatment was conducted in mid-December 2019. Sessions continued once weekly for a total of eight sessions. The ulcer closed after three treatment sessions, and the lateral ulcer wound closed after six treatment sessions. Both wounds remained closed on the day of the last ESWT treatment.<sup>21</sup>



### 3

#### *Bilateral lower extremity ulcers*

This patient was a 52-year-old man with non-healing bilateral DFUs (two right plantar ulcers and one left foot ulcer), which developed after walking in a zero-gravity boot while he was on vacation. He had diabetes mellitus. The DFUs had been debrided and were dressed with mupirocin, and Silvadene® cream 1% was being regularly applied. At the start of ESWT treatment, the first right plantar ulcer had been open for four months, the second had been open for three months, and the left foot ulcer had been open for one month.<sup>21</sup>

The patient also reported that the DFUs had been recurring for approximately three years following a fracture of the left leg, although the ulcers appeared only once annually. The left foot DFU received Dermagold 100® ESWT once weekly for a total of nine treatments. The wound closed after five treatment sessions and remained closed on the day of the last session.<sup>21</sup>

## Conclusion

Wounds heal faster with ESWT than without it. Moreover, wound care is expensive—costs can quickly accumulate with non-healing and complex wounds. ESWT has the potential to decrease medical costs associated with DFU and second-degree burn treatment by shortening the healing time for these wounds.

As the research demonstrates, ESWT can be extremely useful in treating wounds, including DFUs and second-degree burns. This treatment improves patient outcomes and decreases costs associated with prolonged care for these wounds. SoftWave DermaGold 100® can help patients heal faster, help clinicians provide better care, and help medical organizations save time and money. Given the tremendous burden that these wounds place on the national health care system, it is crucial that health care providers use every tool they can to achieve better outcomes. DermaGold 100® is one of the best resources available.

**To learn more about how ESWT and DermaGold 100®  
can support wound healing, contact one of our  
representatives or visit us online at  
[www.softwavetr.com](http://www.softwavetr.com).**

#### **SoftWave Tissue Regeneration Technologies**

Website: [www.softwavetr.com](http://www.softwavetr.com)

Email: [wspencer503@yahoo.com](mailto:wspencer503@yahoo.com)

Phone: (888) 862-6162

1. Nussbaum SR, Carter MJ, Fife CE, et al. An economic evaluation of the impact, cost, and Medicare policy implications of chronic nonhealing wounds. *Value Health*. 2018;21(1):27-32.
2. Raghav A, Khan ZA, Labala RK, et al. Financial burden of diabetic foot ulcers to world: a progressive topic to discuss always. *Ther Adv Endocrinol Metab*. 2018;9(1):29-31.
3. Ren Y, Chang P, Sheridan RL. Negative wound pressure therapy is safe and useful in pediatric burn patients. *Int J Burns Trauma*. 2017;7(2):12-16.
4. Gologorsky R, Arora S, Dua A. Negative-pressure wound therapy to reduce wound complications after abdominoperineal resection. *Perm J*. 2020;24:19.173. <https://doi.org/10.7812/TPP/19.173>
5. Zhang L, Weng C, Zhao Z, Fu X. Extracorporeal shock wave therapy for chronic wounds: a systematic review and meta-analysis of randomized controlled trials. *Wound Repair Regen*. 2017;25:697-706.
6. Wang S, Yin C, Han X, et al. Improved healing of diabetic foot ulcer upon oxygenation therapeutics through oxygen loading nanoporous carbon triggered by radial extracorporeal shock wave. *Oxid Med Cell Longev*. 2019;2019:5738368.
7. Huang Q, Yan P, Xiong H, et al. Extracorporeal shock wave therapy for treating foot ulcers in adults with type 1 and type 2 diabetes: a systematic review and meta-analysis of randomized controlled trials. *Can J Diabetes*. 2020;44(2):196-204.e3.
8. Armstrong DG, Boulton AJM, Bus SA. Diabetic foot ulcers and their recurrence. *N Engl J Med*. 2017;376(24):2367-2375.
9. Vorstenbosch J. Thermal burns. *Medscape*. 2019. <https://emedicine.medscape.com/article/1278244-overview>. Accessed March 25, 2021.
10. Samhan AF, Abdelhalim NM. Impacts of low-energy extracorporeal shockwave therapy on pain, pruritus, and health-related quality of life in patients with burn: a randomized placebo-controlled study. *Burns*. 2019;45:1094-1101.
11. Moortgat P, Anthonissen M, Van Daele U, et al. Shock wave therapy for wound healing and scar management. In: Teot L, Mustoe TA, Middelkoop E, Gauglitz GG, eds. *Textbook on Scar Management*. Cham, Switzerland: Springer; 2020. [https://doi.org/10.1007/978-3-30-44766-3\\_55](https://doi.org/10.1007/978-3-30-44766-3_55).
12. Lin P, Sermersheim M, Li H, et al. Zinc in wound healing modulation. *Nutrients*. 2018;10(16):1-20.
13. Wang CJ. Extracorporeal shockwave therapy in musculoskeletal disorders. *J Orthop Surg Res*. 2012;7(1):11. doi:10.1186/1749-799X-7-11.
14. Wang CJ. An overview of shockwave therapy in musculoskeletal disorders. *Chang Gung Med J*. 2003;26(4):220-232.
15. Cleveland RO, Chitnis P, McClure SR. Acoustic field of a ballistic shockwave therapy device. *Ultrasound Med Biol*. 2007;33(8):1327-1335.
16. Thiel M, Nieswand M, Dorffel M. The use of shockwaves in medicine – a tool of the modern OR: an overview of basic physical principles, history, and research. *Minim Invasive Ther Allied Technol*. 2000;9(3-4):247-253.
17. D'Agostino MC, Craig K, Tibalt E, Respizzi S. Shockwave as biological therapeutic tool: from mechanical stimulation to recovery and healing, through mechanotransduction. *Int J Surg*. 2015;24(Pt B):143-146.
18. Wang YC, Chen SJ, Huang PJ, et al. Efficacy of different energy levels used in focused and radial extracorporeal shockwave therapy in the treatment of plantar fasciitis: a meta-analysis of randomized placebo-controlled trials. *J Clin Med*. 2019;8(9):1497.
19. MTS Science. Technology assessment. Wound Care Dermagold 100. 2017. [https://www.trtlc.com/uploads/5/9/7/2/59724091/mts\\_dg100\\_science\\_wound\\_care.pdf](https://www.trtlc.com/uploads/5/9/7/2/59724091/mts_dg100_science_wound_care.pdf). Accessed March 25, 2021.



20. Wolff KS, Wibmer A, Pusch M, et al. The influence of comorbidities and etiologies on the success of extracorporeal shockwave therapy for chronic soft tissue wounds: midterm results. *Ultrasound Med Biol.* 2011;37(7):1111-1119.
21. Schaden W, Thiele R, Kolpl C, et al. Shockwave therapy for acute and chronic soft tissue wounds: a feasibility study. *J Surg Res.* 2007;143(1):1-12.
22. AUTHOR. Clinical benefit of DermaGold extracorporeal shock wave therapy in wound healing: a meta-analysis of efficacy and safety. PUBLICATION SUBMITTED TO. *Pre-Publication*
23. Marcus B. Extracorporeal shock wave therapy (ESWT) for the treatment of chronic non-healing wounds: a case series. *Stem Cell Regen Med.* 2020;4(2):1-7.
24. Wang C, Cheng J, Kuo Y, Schaden W, Mittermayr R. Extracorporeal shockwave therapy in diabetic foot ulcers. *Int J Surg.* 2015;24(Pt B):207-209.
25. Dumfarth J, Zimpfer D, Vögele-Kadletz M, et al. Prophylactic low-energy shockwave therapy improves wound healing after vein harvesting for coronary artery bypass graft surgery: a prospective randomized trial. *Ann Thorac Surg.* 2008;86(6):1909-1913.